


PATIENT

Mazzi Perantinos

PRESENTING CLINICAL SIGNS

History: Grade 3/6 heart murmur.

SPECIES

Feline

ECHOCARDIOGRAM FINDINGS

2D, m-mode, color flow and doppler imaging is available. The left ventricular wall is normal to decreased in dimension with an irregular appearance. There is a mildly hyperechoic endocardium consistent with fibrosis. The LV is borderline dilated with adequate myocardial function. Atypical fibrosis tissue seen within the LV. The papillary muscles are mildly remodeled. The left atrium is severely dilated and bulbous in appearance. The right atrium is mildly increased in size. The right ventricle appears normal. The mitral valve is normal in structure and mobility. Mild MR. No TR. Blood flow through both the LVOT and RVOT is normal in velocity. No pleural or pericardial effusion seen. No obvious cardiac tumors.

BREED

Oriental Shorthair

SEX

Male Neutered

CARDIAC CHART
AGE

5 years

WEIGHT

9.5lbs

INTERPRETED BY

 Maggie Machen Lamy,
 DVM DACVIM
 (Cardiology)

FELINE CARDIAC PARAMETERS	BODY WEIGHT (kg)	HR (BPM)	IVSd (cm) <small>(Moise, Pipers)</small>	LVIDd (cm) <small>(Moise, Pipers)</small>	LVWd (cm) <small>(Moise, Pipers)</small>	FS (%)	EF (%)
NORMAL PARAMETER	-----	150-240	0.35-0.55	<2 (mean 1.5)	3.5-0.55	35-67	80-100
PATIENT	4.3	227	0.39	1.75	0.38	50	92
FELINE CARDIAC PARAMETERS	LA/AO <small>(Boon)</small>	LA/AO HEART BASE (Swe) <small>(Abbott)</small>	LA 2D short axis Base view (cm) <small>(Abbott)</small>		LVOT VEL <small>(m/s)</small>	RVOT VEL <small>(m/s)</small>	E max <small>(m/s)</small>
NORMAL	<1.5	<1.3	<1.2		<1.6	<1.3	<0.9
PATIENT	2.7	2.1	1.9		2.4	1.2	NM

**Note: All measurements based upon multi-modal images and methods. An average value is reported.*

Adapted from June Boon, Veterinary Echocardiography, 1998

Abbott J & MacLean H JVIM 2006;20: 111-119, Moise et al. Am J Vet Res 47:1476, 1986. Pipers et al. Am J Vet Res 40:882, 1979.

IMAGING PERFORMED BY

Crystal Hill, RVT

INTERPRETATION OF THE FINDINGS & FURTHER RECOMMENDATIONS

The finding of severe LA dilation in the face of an irregular LV wall appearance is most consistent with unclassified/restrictive cardiomyopathy (RCM/UCM); however, some prior infectious or inflammatory insult to the myocardium cannot be definitively ruled out. There is normal wall thickness, ruling out typical hypertrophic disease. Serial echocardiography will be helpful to confirm the diagnosis and assess for progression going forward.

HOSPITAL NAME

East Credit Veterinary Hospital

REFERRING VET

Dr. Webster

INVOICE

24474

DATE

5/30/22

Regardless of categorical classification, the finding of severe left atrial dilation is highly concerning as there is high risk for clinical decompensation in the near future, and lifelong medications are warranted as below including low dose diuretic therapy and off-label Pimobendan. The mean survival time for cats once CHF develops is 8-12 months, however most are able to maintain a good quality of life on medications. There will always remain risk for progression to CHF and development of blood clots in the future. Monitoring of sleeping breathing rates at home is recommended as the best way to screen for CHF at home.



PATIENT

Mazzi Perantinos Elective anesthesia, fluid or steroid therapy is not advised.

SPECIES

Feline

PLAN

Institute diuretic Lasix 1mg/kg PO q12h. Institute blood thinner Clopidogrel (Plavix) 75mg tablets; give ¼ tab orally once daily (NOTE: this medication is very bitter on the cut edges). Institute Pimobendan 1.25mg PO q12h. *Note: If patient is difficult to medicate, Pimobendan and Plavix would be most important.

BREED

Oriental Shorthair Recheck renal values and BP in 10-14 days to ensure tolerance of medications, then every 4-6 months lifelong. If BP is >130mmHg and patient is easily medicated, institute ACE-I 0.5mg/kg PO q12h.

SEX

Male Neutered A recheck echocardiogram is recommended in 6 months to assess progression.

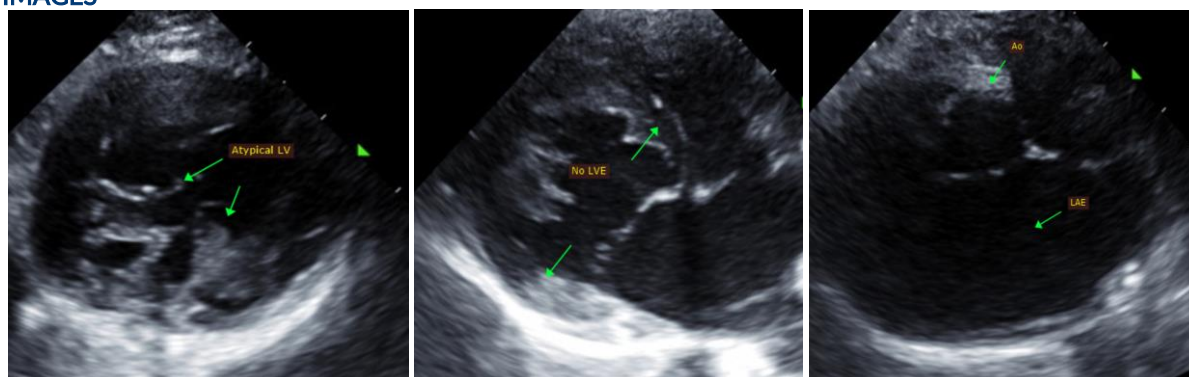
AGE

5 years

IMAGES

WEIGHT

9.5lbs



INTERPRETED BY

Maggie Machen Lamy, DVM DACVIM (Cardiology)

The information and recommendations provided are based on the images presented by the referring veterinarian. No evaluation can be communicated regarding pathology that was not visible in the image/video clips provided.

IMAGING PERFORMED BY

Crystal Hill, RVT

Thank you for this referral. This report was generated using transcription software, and minor dictation errors may be present. If the clinical or image interpretation does not parallel your findings or if I can be of any further assistance, please contact me.

HOSPITAL NAME

East Credit Veterinary Hospital

Maggie Machen Lamy, DVM
Diplomate of the American College of Veterinary Internal Medicine (Cardiology)
info@sonopath.com

REFERRING VET

Dr. Webster

INVOICE

24474

DATE

5/30/22